

Original Research

Mandibular reconstruction with non-vascularized bone graft in a double bridging technique

*Obitade Sunday Obimakinde¹, Sunday Ogunsuyi Popoola², Kehinde Olubukola Ojo³, Moruf Babatunde Yusuf², John Adetunji Omotayo⁴, Akinwale Olaleye Akinbade⁵

¹ Oral and Maxillofacial Surgery Department, College of Medicine, Ekiti State University/ Ekiti State University Teaching Hospital, Ado-Ekiti, Nigeria. ²Orthopaedic and Trauma Surgery, Department of Surgery, College of Medicine, Ekiti State University/ Ekiti State University Teaching Hospital, Ado-Ekiti, Nigeria. ³Oral Medicine, College of Medicine and Health Sciences, Afe Babalola University, Ado-Ekiti, Nigeria ⁴Anatomic Pathology Department, Faculty of Basic Clinical Sciences, College of Medicine, Ekiti State University, Ado-Ekiti, Nigeria, ⁵Oral and Maxillofacial Surgery Department, Federal Teaching Hospital, Ido-Ekiti, Nigeria.

Abstract

Background: Reconstruction of the mandible following tumor resection or trauma can be challenging due to associated functional and esthetic problems. Various options have been described in the literature, but non-vascularized bone graft remain a viable option in middle- and low-income countries, Nigeria inclusive. We hereby report our experience with the use of non-vascularized bone graft with mandibular reconstruction plates in a double bridging technique for mandibular reconstruction in our institution.

Methodology: Patients who had mandibular defect reconstruction with non-vascularized bone graft between January 2012 and December 2021 were included in this study. Grafts were harvested from either the rib or contralateral iliac crest and secured with mandibular reconstruction plate and screws in a double bridging technique. Patients were followed for a minimum of 12 months and outcomes such as the level of patients' satisfaction with appearance, graft take, bony continuity and complications were assessed and analyzed.

Result: Twenty eight patients comprising 18 males and 10 females [M:F 1.8:1] had mandibular defect reconstruction with double bridging technique during the study period. Donor site distribution revealed that 64.3% [n=18] had their grafts harvested from the iliac crest while the remaining 10 [35.7%] were taken from the rib. Ameloblastoma [75%, n=21] was the commonest lesion necessitating resection of the mandible amongst the subjects. The follow up result showed that appearance was satisfactory in 25 patients [89%], graft take/ restoration of bony continuity in 27 patients [96%], graft infection occurred in 2 patients [7.1%] while only one case of graft failure was established [3.6%]

Conclusion: A combination of non-vascularized bone graft with reconstruction plate in a bridging technique is a viable option for mandibular reconstruction in a resource-limited setting.

Keywords: Mandibular Defect; Bone Graft; Reconstruction Plate; Iliac Crest; Rib.

***Correspondence:** Obitade. S Obimakinde. Oral and Maxillofacial Surgery Department, College of Medicine, Ekiti State University/ Ekiti State University Teaching Hospital, Ado-Ekiti, Nigeria. **Email:** obitade.obimakinde@eksu.edu.ng

How to cite: Obimakinde OS, Popoola SO, Ojo KO, Yusuf MB, Omotayo JA, Akinbade AO. Mandibular reconstruction with non-vascularized bone graft in a double bridging technique. Niger Med J 2025; 66 (1):91-98. <https://doi.org/10.71480/nmj.v66i1.581>.

Quick Response Code:



Introduction

Mandibular bone defects due to resection of a pathologic lesion or trauma can result in loss of bone continuity and create a ‘socially mutilated’ patient due to loss of function and aesthetics [1–4]. Treatment of neoplastic diseases of the oral cavity was reported as the commonest aetiology of continuity defect of the mandible [2–5]. Other causes of mandibular defects include trauma, infection, osteoradionecrosis, and congenital deformities [4–7]. Due to the important role, the mandible plays in speech, mastication, and aesthetics, thus it is necessary to reconstruct mandibular continuity defects to restore appearance and functions [2,7,8].

Various options available for the reconstruction of the mandible that have been reported include vascularized bone graft, non-vascularized graft, alloplastic implants, and xenografts [5–10]. Distraction osteogenesis by bone transport is a novel approach but its use is largely restricted to small mandibular defects [7,8,10]. Genetically engineered bone growth is a new modality that has received attention in literature, however, high costs, lack of facilities, and dearth of expertise remain major limitations to its application in a resource-limited economy. [3,6,8]. Reconstruction of the mandible with bone grafts [either vascularized or non-vascularized] remained the traditionally preferred method in most middle and low-income countries [4,6,9,11–14]. A vascularized bone graft or bone flap is preferred to a non-vascularized graft because it offers good blood supply for graft take and soft tissue support [4,13,15]. However, its use in a poor resource setting like ours is limited partly due to a lack of personnel for two separate surgical teams (tumour ablation team and reconstructive team), expertise for microvascular tissue transfer, and other factors such as high cost of treatment, prolong hospital stay and attendant morbidities [6,8,10,16]. These limitations made non-vascularized autogenic graft the mainstay of mandibular reconstruction in most low-income countries including Nigeria. The common donor sites that have been described include the rib, ilium, tibia, fibula, scapula, radius, and calvarium [2,5,6,9,10,16]. The limitations of autogenic non-vascularized grafts are susceptibility to infection and unusual rapid resorption especially in ablative cases requiring adjuvant radiotherapy [6,8,12,13]. Also, graft take can be compromised if graft anchorage is not achieved with a rigid fixation technique. Therefore, some authors have advocated the employment of a rigid reconstruction plate in a double bridging technique with a non-vascularized bone graft for mandibular reconstruction [8,16].

The use of mandibular reconstruction plates and non-vascularized bone graft in a double bridging technique for mandibular defect reconstruction has not been sufficiently reported in the literature. This formed the basis for the current study which aimed to report on our experience with this technique.

Methodology

Cases of mandibular defect reconstruction managed by the Oral and Maxillofacial Surgery team at Ekiti State University Teaching Hospital within a ten-year period between January 2012 and December 2021 were recruited for this study. Patients’ cohorts include cases of benign mandibular lesions necessitating resection and mandibular defects due to trauma. Patients with malignant mandibular lesions and those treated for benign mandibular lesions but had other means of reconstruction were excluded from the study. Ethical approval for this study was obtained from our Institution’s Ethical review board.

Patients’ records including demography, aetiology of mandibular defect, anatomic location and length of the defects, postoperative records of graft survival, and complications were recorded on patients’ individual proforma. All patients in this series had reconstruction with either iliac crest or rib graft in a double bridging technique using a titanium reconstruction plate [2.4 mm] for graft anchorage. Graft harvest was done after tumour resection and immediate reconstruction of the mandible was achieved by anchoring the graft to the recipient bone with the reconstruction plate. Using the classification method described by Urken et al [15], we classified the mandibular defects in this study as; central, lateral, combined central and lateral defects, and free end or posterior mandibular defects [defect involving

disarticulation of the condyle]. Defects involving more than one-half of the mandible were classified as subtotal resection, while less than one-half of the mandible was classified as partial resection.

All surgeries were performed under general anaesthesia and patients were followed up for a period of 12 months post-reconstruction. Successful reconstruction was defined as restoration of bony continuity, graft stability, and long-term maintenance of osseous bulk. Aesthetics was measured using Visual Analogue Scale (VAS) [1-10cm]. Scores greater than 5 indicates higher degree of satisfaction while scores less than 5 indicate that the patient was less satisfied. Measurements were taken twice [(at 1 month and 6 months) postoperatively and an average for each patient was recorded. Descriptive variables were analysed with SPSS version 20.

Results

Twenty-eight [28] patients had mandibular reconstruction with non-vascularized bone grafts during the study period. There was a male preponderance with male-to-female ratio of 1.8:1[18 males and 10 females]. The age range of the patients was 21 to 65 years with a mean age of 32.7 ± 8.33 years. Aetiology of defects showed that resection of Ameloblastoma was the commonest [75%, n=21], Gunshot injury with significant bone loss accounted for 3 cases while fibromyxoma and keratocystic odontogenic tumour accounted for 2 cases each [Figure 1].

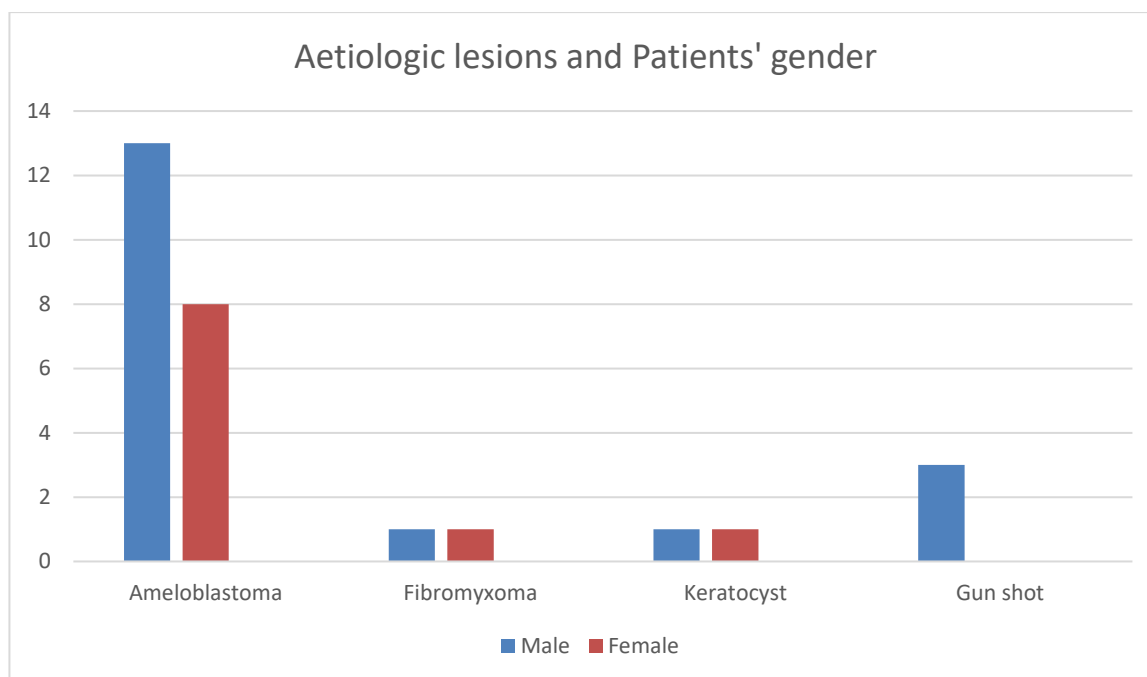


Figure 1: Patient gender distribution and aetiologic lesions for mandibular defect

Regarding defect location, lateral defect due to segmental resection of the mandible was the commonest [50%, n=14] while central defects [10.7%, n=3] involving the anterior part of the mandible were the least encountered among the patients treated [Table 1]. All patients in this series had immediate reconstruction of the mandible with either an iliac crest bone graft [n=18] or a costochondral rib graft [n=10]. All the patients with lateral and posterior defects which involved condylar disarticulation had iliac crest grafts while defects involving the anterior mandible had costochondral rib grafts. The Defect span: ranges from 6cm to 20cm with a mean length of 11.5 ± 6.2 cm. The duration of hospital stays after surgery ranged from 7 to 14 days with a mean duration of 10 days.

Table I: Distribution of defect location and Aetiologic lesion

Aetiologic lesion	Anterior	Anterolateral	Lateral	Posterolateral
Ameloblastoma [21]	3	4	9	5
Keratocyst [2]	-	-	1	1
Fibromyxoma [2]	-	-	2	-
Gunshot [3]	-	1	2	-
Total [28]	3 [10.7%]	5 [17.9%]	14 [50%]	6 [21.4%]

Graft take was successful in 27 [96%] patients [iliac crest n=18, rib graft n=9]. There were 2 cases [7.1%] of persistent graft infection [one each from the rib and iliac crest] during the postoperative period. The rib graft was removed due to confirmed graft failure, which was caused by persistent, recurrent infection. Other complications included six cases of gait disturbance [for iliac crest bone graft] and 3 cases of intraoral wound dehiscence [iliac crest 2, rib graft 1]. All the patients who had postoperative gait disturbance had complete resolution within 1 month of surgery. There were no cases of nerve disturbance in the form of paraesthesia from the iliac rest donor site.

The visual analogue score for appearance was satisfactory in 25 [89%] patients [iliac crest n=17, rib graft n=8] with an overall average of 7.6. Also, the average score for patients who had rib graft and iliac crest were comparable [7.8 and 7.4 respectively].

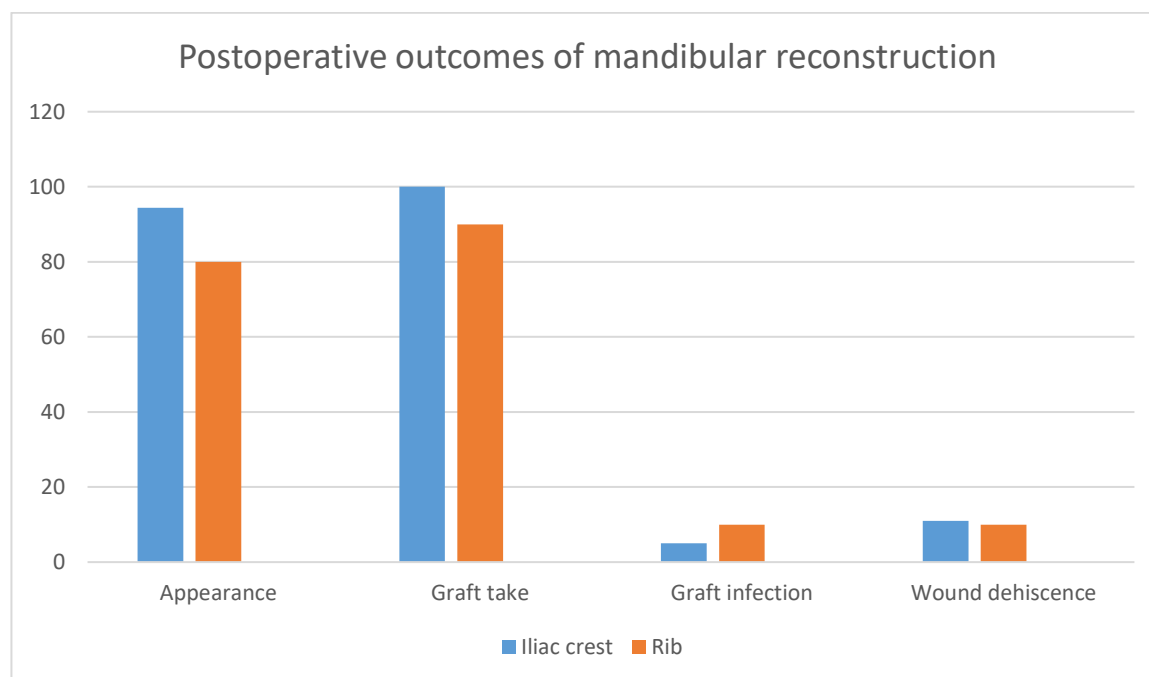


Figure 2: Postoperative outcomes of mandibular defect reconstruction.

Discussion

Reconstruction of mandibular bone defects following tumour resection or trauma remains a challenge to the oral and maxillofacial surgeon especially in low and middle-income countries where expertise and armamentarium are scarce [2,5,6,8,10]. The attendant aesthetic and functional challenges have made it imperative for the surgeon to consider a workable and result-oriented reconstruction method within the ambit of available resources [1,9,16]. The male preponderance observed in this study is commensurate with the findings from similar studies by Okoje et al [6], Omeje et al [17], and Ogunlade et al [18]. However, a study by Braimah et al [8] in the Northwestern part of Nigeria reported a higher female preponderance. In agreement with previous reports from similar studies, resection for ameloblastoma remained the commonest aetiology of the mandibular bone defect [2,6,7,8,10,16,17]. Ameloblastoma is the most common jaw tumour globally and the significant aesthetic compromise due to late presentation in sub-Saharan Africa is a major reason why its resection often results in significant continuity defect of the mandible.

Regarding the location of mandibular defects, we observed that the lateral and posterior mandibular defects were more commonly encountered in this series (50% and 21.4% respectively) compared to the anterior part of the bone. Our findings are similar to previous reports by Obiechina et al [2], Ndukwe et al [5], Brahima et al [8], and Arotiba et al [10]. This may be because ameloblastoma, being the most common benign jaw neoplasms, has a higher predilection for the posterior part of the mandible among black Africans compared to the anterior mandible [6].

Despite the long span of most of the defects in this study, our graft take was good [96%, n=27]. This contradicts the study by Pogrel et al [13] which reported 25% graft failure for defects with a span longer than 12cm. They advocated for the use of microvascular composite flaps for such defects in their study. However, we opined that our high rate of graft take may be explained by the fact that the reconstruction plate offers good stability and milieu for unhindered graft takes with the double bridging technique employed. Also, our grafts were secured to the recipient's bone in a butt joint which also aids graft take. To further enhance graft immobility, our patients had mandibulo-maxillary fixation [MMF] with 0.5mm soft stainless-steel wires on the contralateral side of the mandible for a period of four weeks postoperatively. This method was also buttressed by Ndukwe et al [5] in their study whereby patients were placed on MMF for a period of 5 weeks after surgery. Tumour recurrence is another factor responsible for graft failure in some studies especially where resection of malignant lesions was involved [15,19,20]. However, none of our patients suffered from tumour recurrence probably because our cohort was limited to benign lesions and in addition, we ensured a safety margin of about 1.5cm of normal bone tissue during tumour excisions in order to avoid recurrence which can lead to graft failure. Traditionally we do not do immediate reconstruction for patients with malignant jaw tumour because of anticipated postoperative radiation treatment and the likelihood of recurrence which can contribute to graft failure.

Appearance was judged satisfactory by 25 of our study participants [89%] with an overall average mean VAS score of 7.6 for aesthetics. This was corroborated by some authors who also reported a high rate of satisfaction in appearance following mandibular reconstruction [1,2,13,21]. It has been reported that the use of stereolithographic models to produce computer-aided contouring and adaptation of reconstruction plates enhances perfection in aesthetics following reconstruction [17]. The non-availability of this technology in a resource-limited setting like ours resulted in the use of freehand manual contouring of the reconstruction plates in all our study participants and the result was good and acceptable to the participants. Also, the comparable mean VAS score for patients who had an iliac crest and costochondral rib graft in this study further buttresses the fact that both rib and iliac crest graft are suitable for mandibular reconstruction despite the differences in bulk, cortical, and cancellous components of both bones [10,22,23,24].

Infection of bone graft as a major cause of graft failure has been widely discussed in the literature [1,7,10,13,25]. The low rate of graft infection in this study is comparable with previous reports by Ogunlade et al^[18] and Ndukwe et al^[5], but lower than those of Brahima et al^[8], Okoje et al^[6], Omeje et al^[17], Pogrel et al^[13] and August et al^[24]. The relatively rigid stability offered by the reconstruction plate results in the prevention of micro-movement of the graft at the graft-graft and graft-mandible interfaces. In addition, the extended postoperative antibiotics regimen for all our patients for a period of 10 days as recommended by Egyedi et al^[25] may explain the comparatively low rate of graft infection in our series.

Postoperative gait disturbance has been reported as a common complication of iliac crest bone graft harvest and six of our study participants who had iliac crest as donor site were involved. Like similar reports [2,7,17], the gait disturbance was temporary as all the patients involved had complete remission within one month of surgery. The initial gait disturbance must have been due to postoperative discomfort due to inflammation. Intraoral wound dehiscence was another complication encountered in 3 [10.7%] of our patients. Two of the study participants were successfully treated by local wound debridement, suturing, and antibiotic medication. The third case of wound dehiscence was the only case of graft failure in our series and the graft had to be excised following persistent unabated infection. Some authors affirmed that intraoral wound dehiscence, oro-cutaneous fistula, graft non-union, graft rotation, or malposition are contributory to graft failure [6,13,22,24,25,26,27].

Conclusion

It can be concluded from this study that non-vascularized bone graft provides an affordable and less technical choice for mandibular reconstruction in developing economies with few complications. Our experience with the use of non-vascularized bone graft in a double bridging technique has shown that it is a viable option for the reconstruction of mandibular bone defects. We, therefore, recommend its use for the reconstruction of mandibular defects resulting from the excision of benign tumors and trauma.

References

1. Mehta RP, Deschler DG. Mandibular reconstruction in 2004: an analysis of different techniques. *Curr Opin Otolaryngol Head Neck Surg.* 2004; 12:288-293.
2. Obiechina AE, Ogunlade SO, Fasola AO, Arotiba JT. Mandibular segmental reconstruction with iliac crest. *West Afr J Med.* 2003; 22(1):46-49.
3. Abukawa H, Shin M, Williams WB, Vacanti JP, Kaban LB, Troulis MJ. Reconstruction of mandibular defects with Autogenous tissue engineered bone. *J Oral Maxillofac Surg* 2004; 62:601-606.
4. Urken ML. Composite free flap in oromandibular reconstruction. *Arch Otolaryngol Head Neck Surg.* 1991; 117:724-732.
5. Ndukwe KC, Aregbesola SB, Ikem IC, Ugboko VI, Adebisi KE, Fatusi OA, Owotade FJ, Braimah RO. Reconstruction of Mandibular Defects Using Nonvascularized Autogenous Bone Graft in Nigerians. *Nigerian Journal of Surgery.* 2014;20(2):87-91.
6. Okojie VN, Obimakinde OS, Arotiba JT, Fasola AO, Ogunlade SO, Obiechina AE. Mandibular defect reconstruction with non-vascularized iliac crest bone graft. *Niger J Clin Pract.* 2012; 15:224-227.
7. Herford AS. Use of a plate-guided distraction device for transport distraction osteogenesis of the mandible. *J Oral Maxillofac Surg.* 2004; 62:412-420.

8. Braimah RO, Ibikunle AA, Abubakar U, Taiwo AO, Oboirien M, Adejobi FA, et al. Mandibular reconstruction with autogenous non-vascularised bone graft. *Afr Health Sci* 2019; 19 (3):2768-2777.
9. Tidstrom KD, Keller EE. Reconstruction of mandibular discontinuity with Autogenous iliac bone grafting: Report of 34 consecutive patients. *J Oral Maxillofac Surg.* 1990; 48(4):336-346.
10. Arotiba JT, Obimakinde OS, Ogunlade SO, Fasola AO, Okoje VN, Akinmoladun VI, Sotunmbi PT, Obiechina E. An audit of mandibular defect reconstruction methods in a Nigerian Tertiary Hospital. *Niger Postgrad Med J.* 2011; 18:172-176.
11. Kumar BP, Venkatesh V, Kumar KAJ, Yadav BY, Mohan SR. Mandibular Reconstruction: Overview. *J. Maxillofac. Oral Surg.* 2016;15(4):425-441.
12. Hull W, Miloro M, Kolokythas A. Is immediate reconstruction of the mandible with non-vascularized bone graft following resection of benign pathology a viable treatment option? *J Oral Maxillofac Surg* 2015; 73:541-549.
13. Pogrel MA, Podlesh S, Anthony JP, Alexander J. A comparison of vascularized and non vascularised bone grafts for reconstruction of mandibular continuity defects. *J Oral Maxillofac Surg* 1997; 55:1200-1206.
14. Aajum S, Khan NA, Ahmad M. Treatment outcomes of reconstruction with iliac bone graft and rib graft in patients with mandibular defects. *Pakistan Oral & Dental Journal.*2013;33(3):423-425.
15. Urken ML, Weinberg H, Vickery C, Buchbinder D, Lawson W, Biller HF. Oromandibular reconstruction using microvascular composite free flaps: report of 71 cases and a new classification scheme for bony, soft tissue, and neurologic defects. *Arch Otolaryngol Head Neck Surg* 1991; 117:733-744.
16. Moura LB, Carvalho PHD, Xavier CB, Prost LK, Torriani MA, Santagata M, Chagas Jr OL. Autogenous non-vascularized bone graft in segmental mandibular reconstruction: a systematic review. *Int. J. Oral Maxillofac. Surg.* 2016;45(11):1388-1394.<http://dx.doi.org/10.1016/j.ijom.2016.05.004>.
17. Omeje K, Efunkoya A, Amole I, Akhiwu B, Osunde D. A two-year audit of non-vascularised iliac crest bone graft for mandibular reconstruction: technique, experience and challenges. *K Korean Assoc Oral Maxillofac Surg*, 2014;40:272-277.
18. Ogunlade SO, Arotiba JT, Fasola AO. Autogenous cortico-cancellous iliac bone graft in reconstruction of the mandibular bone defect: point of technique. *Afr J Biomed Res.* 2010; 13:157-160.
19. Bai XF, Wushou A, Zheng J, Li G. An alternative approach for mandible reconstruction. *J Craniofac Surg* 2013;24(2):195–198. <http://dx.doi.org/10.1097/SCS.0b013e3182802269>
20. Hayden RE, Mullin DP, Patel AK. Reconstruction of the segmental mandibular defect: current state of the art. *Curr Opin Otolaryngol Head Neck Surg* 2012;20:231–236. <http://dx.doi.org/10.1097/MOO.0b013e328355d0f3>

21. Alfotawi R, Ayoub A. Reconstruction of maxillofacial bone defects: Contemporary methods and future techniques. *Am J Adv Med Sci.* 2014;2(1):18-27.
22. Sajid MA, Warraich RA, Abid H, Ehsan-ul-Haq M, Shah KL, Khan Z. Reconstruction of mandibular defects with autogenous bone grafts: a review of 30 cases. *J Ayub Med Coll Abbottabad.* 2011;23(3):82-5.
23. Donkor P, Bankas DO, Boakye G, Ansah S, Acheampong AO. The use of free autogenous rib grafts in maxillofacial reconstruction. *Ghana Medical Journal.* 2006;40(4):127-131.
24. August M, Tompach P, Chang Y, Kaban L. Factors influencing the long-term outcome of mandibular reconstruction. *J Oral Maxillofac Surg.* 2000; 58:731-737.
25. Egyedi P. Wound infection after mandibular reconstruction with autogenous graft. *Ann Acad Med Singapore* 1986; 15:340-345.
26. Chiapasco M, Colletti G, Romeo E, Zaniboni M, Brusati R. Long-term results of mandibular reconstruction with autogenous bone grafts and oral implants after tumor resection. *Clin Oral Implants Res* 2008; 19:1074–1080. <http://dx.doi.org/10.1111/j.1600-0501.2008.01542>.
27. Van Germet JT, Van Es RJ, Van Cann EM, Koole R. Nonvascularized bone grafts for segmental reconstruction of the mandible: a reappraisal. *J Oral Maxillofac Surg* 2009; 67:1446–1452. <http://dx.doi.org/10.1016/j.joms.2008.12.052>.