

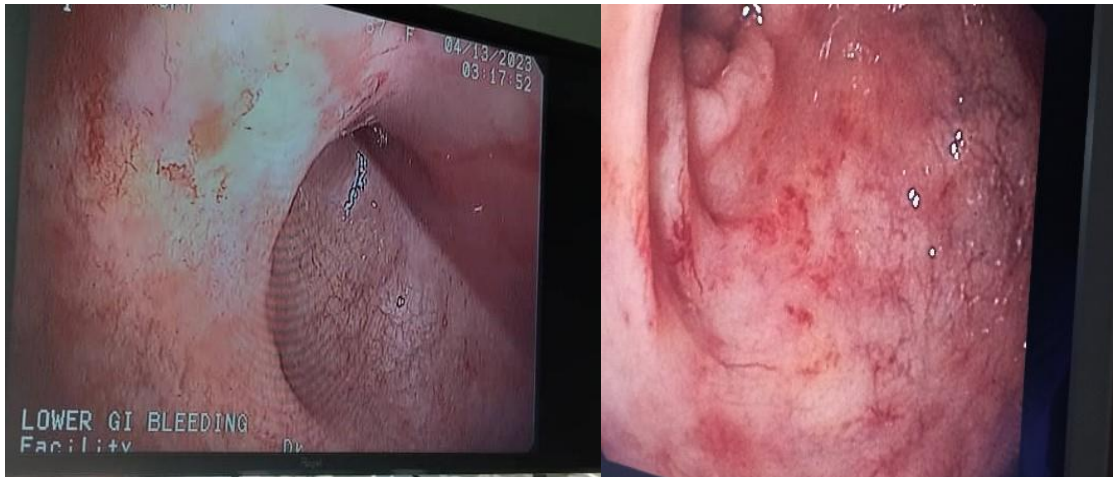Case Report

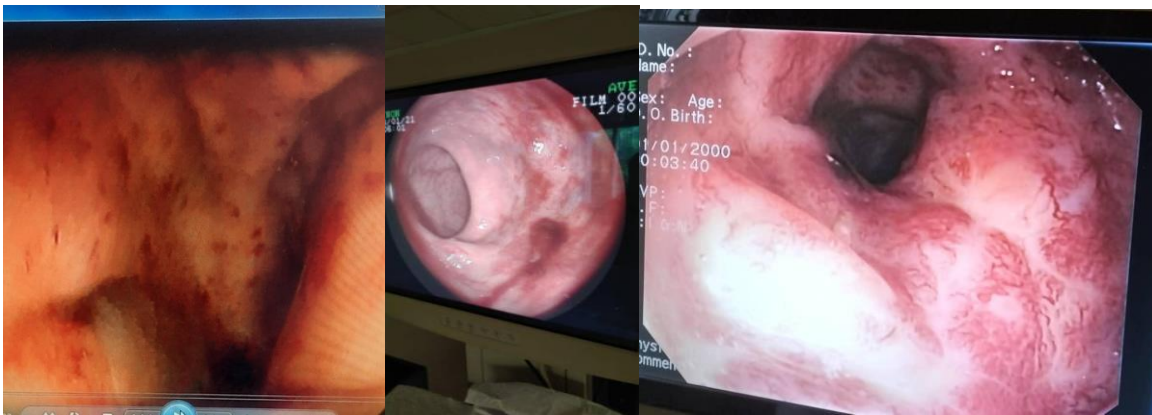
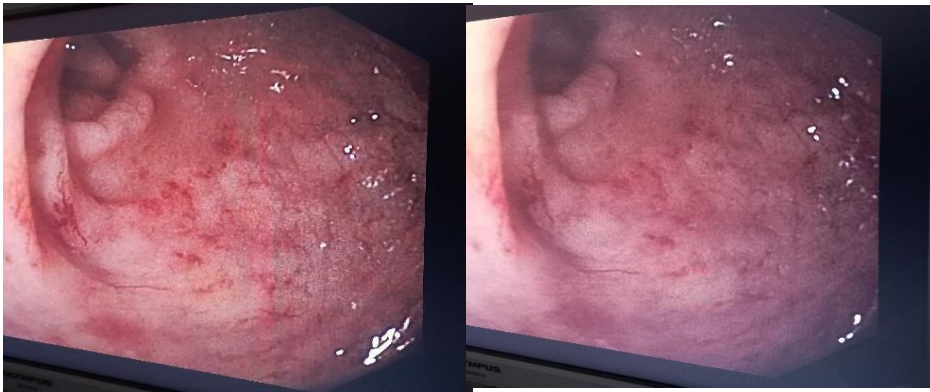
**Radiation proctitis as a differential of lower GIT bleeding in Nigeria: A case series.**

**Evaristus Sunday Chukwudike<sup>1</sup>, Nyam Paul David<sup>2</sup>, Emmanuel Obasi<sup>3</sup>, John John Ogan<sup>4</sup>, Chinenye Unoma Nwoko<sup>5</sup>, Chinwe Philomena Onyia<sup>6</sup>, Kenechukwu Chukwuemeka Okonkwo<sup>7</sup>, Lukman Olaitan, Abdulkareem<sup>8</sup>, Winnifred Njideka Adiri<sup>6</sup>, Stella-Maris Chinma Egbo<sup>9</sup>, Egbo Oziegbe<sup>10</sup>, \*Pantong Mark Davwar<sup>2</sup>**

<sup>1</sup>University of Calabar Teaching Hospital, Calabar, Nigeria, <sup>2</sup>Jos University Teaching Hospital, Jos, Nigeria, <sup>3</sup>Alex Ekwueme Federal University Teaching Hospital, Abakiliki, Nigeria, <sup>4</sup>University of Port Harcourt teaching Hospital, Port Harcourt, Nigeria, <sup>5</sup>Iwosan Lagoon Hospital Lagos, Lagos, Nigeria, <sup>6</sup>University of Nigeria Teaching Hospital Ituku Ozalla, Enugu, Nigeria, <sup>7</sup>Federal Medical Centre, Owo, Nigeria, <sup>8</sup>University of Abuja Teaching Hospital, Gwagwalada, Abuja, Nigeria, <sup>9</sup>Federal Medical Centre, Yenagoa, Nigeria, <sup>10</sup>Ripple Medical Center, Benin, Nigeria.

**Supplementary Files: Images of Colonoscopy for the patients**





**Figure 1: Images of patient's colonoscopy.**