

## Acute Appendicitis Incidence, Diagnostic Markers, and Sequelae; Dallah Hospital-Based Study in Riyadh, Saudi Arabia

**Marwa M Suliman<sup>1</sup>, Amira E Raslan<sup>1</sup>, Saeda A Salih<sup>2</sup>, Salah M Soliman<sup>3</sup>, Salwa S Abdullah<sup>4</sup>, Entesar H Elnoor<sup>5</sup>, Mohamed B Ibrahim<sup>6</sup>, Ahmed M Elnaggar<sup>1</sup>, Marwan M Badawi,<sup>7</sup>**

<sup>1</sup>Radiology Department, Dallah Hospitals, Riyadh, Saudi Arabia, <sup>2</sup>Radiology Department, Obaid Specialized Hospital, Riyadh, Saudi Arabia, <sup>3</sup>Radiology Department, Al-Qadisiyya Medical Centre, Riyadh, Saudi Arabia <sup>4</sup>Radiology Department, Kingdom Hospital, Riyadh, Saudi Arabia, <sup>5</sup>Radiology Department, Al-Maali Medical Complex, Buraidah, Al-Qassim, Saudi Arabia, <sup>6</sup>Urology Department, Dallah Hospitals, Riyadh, Saudi Arabia <sup>7</sup>Medical Unit, Higher Academy for Strategic and Security Studies, Khartoum, Sudan

### Abstract

**Background:** Acute appendicitis is currently considered one of the most common acute surgical diseases of the abdomen and requires emergency surgery. It is also one of the most common abdominal emergencies in both developed and developing countries. The current study is aimed at assessing the specificity and sensitivity of Ultrasound and Computed Tomography in the diagnosis of appendicitis as well as the prevalence of its complications. The association of appendicitis with several laboratory findings will also be evaluated.

**Methodology:** A retrospective study was conducted at Dallah-Namar Hospital, Riyadh City, Saudi Arabia.

**Results:** 720 patients were differentially diagnosed with appendicitis in the study area. Of these, 618 patients had US abdomen/pelvis, with 15 (2.4%) showing positive findings. Amongst the 203 patients noted to have undergone abdominal CT, 8 (4.0%) was found to have positive findings.

**Conclusion:** The sensitivity of the US was determined to be relatively low. Also, serum creatinine was found to be elevated among all patients diagnosed with appendicitis. Further research with a larger sample size is needed to be conducted to further support the current findings.

**Keywords:** Diagnostic Markers, Middle East, Imaging Ultrasonography, Computed Tomography, Appendicitis.

\***Correspondence:** Marwan M Badawi, Medical Unit, Higher Academy for Strategic and Security Studies, Khartoum, Sudan

**E-mail :** mmbadwi44new@gmail.com.

**How to cite:** Suliman MM, Raslan AE, Salih SA, Soliman SM, Abdullah SS, Elnoor EH, Ibrahim MB, Elnaggar AM. Acute Appendicitis Incidence, Diagnostic Markers, and Sequelae; Dallah Hospital-based Study in Riyadh, Saudi Arabia. Niger Med J 2024; 65 (1):67-74

Quick Response Code:



This is an open access journal, and articles are distributed under the terms of the Creative Commons Attribution-Non-Commercial-Share Alike 4.0 License, which allows others to remix, tweak, and build upon the work non-commercially, as long as appropriate credit is given, and the new creations are licensed under the identical terms.

## Introduction

Acute appendicitis, previously known as peri typhlitis is currently considered one of the most common acute surgical diseases of the abdomen and one of the most common abdominal emergencies in developed as well as developing countries. [1-4]

The prevalence rate of acute appendicitis among the total population is reported to be around 6%, more common between 10 and 30 years old. In the United States, for instance, this condition occurs at a rate of 8% in men and about 7% in women. The lifetime risk of appendicitis shows an annual incidence of 9.38/100,000 persons. Moreover, in 2015 there were 11.6 million cases of appendicitis that resulted in more than 50,100 deaths. Furthermore, only in 2007, it is estimated that about 326,000 appendectomies were performed in developing countries and incidence reached up to 8% for appendicitis. [5-7]

The cause of acute appendicitis remains unclear but often occurs with the lumen obstructed by fecolith, tumor, or a foreign matter. Inflammation increases pressure within the lumen as well as the walls of the appendix. This increased pressure leads to thrombosis and occlusion of the small vessels, with resultant lymphatic flow stasis. At this point, spontaneous recovery is less likely to occur, and appendectomy will be the standard treatment as it significantly lowers the risks of perforation and other associated complications. [8, 9]

Typical cases of acute appendicitis are diagnosed with a physical examination based on a history of shifting central abdominal pain, anorexia, nausea, and vomiting. In some cases, atypical abdominal pain can setback the diagnosis, and complications such as abscess, fluid collection, and peritonitis can be found; thus, the importance of radiological investigation becomes evident. [10] A recent study published in (2019) and conducted at King Fahad Specialist Hospital in Buraidah, Saudi Arabia has concluded that 86% of *CT* findings were diagnostic for appendicitis while only 37% were diagnosed by *US* among 200 participants. [2]

This study is aimed to further assess the specificity and sensitivity of *US* and *CT* in regard to appendicitis diagnosis as well as the prevalence of appendicitis complications. Moreover, associations between appendicitis with several laboratory findings are to be investigated as well.

## Methodology

The current study was a retrospective study at Dallah-Namar Hospital. The hospital is one of the leading healthcare facilities in the private sector of Riyadh City, Saudi Arabia, and almost 400 patients visit the hospital every day for various medical needs.

Records of all patients admitted to the Emergency room from the 1<sup>st</sup> of July till the 30<sup>th</sup> of September 2023 were scrutinized. However, only patients clinically differentially diagnosed as having appendicitis were included in this study. Patients below 5 or above 50 years were excluded. Furthermore, patients who were discharged before undergoing the requested investigations were also excluded.

The *CT* machines used were SIEMENS (SOMATOM Definition AS) and General Electric (Revulsion Evo), while the *US* equipment used were General Electric (LOGIQ E9), PHILIPS (EPIQ 7G), and PHILIPS (Affiniti 70G).

## Data collection

Data was retrospectively collected from patients' files, and radiological (*US*, *CT*), as well as histopathological findings were extracted. Moreover, total white blood cell count (TWBCs), C-Reactive

Protein (CRP), and Serum creatinine level were also extracted. Data was first de-identified and then carefully reviewed.

*CT* scan was conducted with oral and IV contrast and it was considered positive when findings indicated an appendiceal dilatation (>6 mm diameter), wall thickening (>3 mm), and enhancement thickening of the cecal apex. Moreover, peri-appendiceal inflammation was witnessed as fat stranding, phlegmon, or abscess formation.

In regard to the *US*, findings were considered positive when blind-ended tubular structure in the right iliac fossa was found to be bigger than 6 mm with inflamed fat and free fluid.

### **Statistical analysis**

Data collected was analyzed using IBM SPSS Statistics for Windows version 22 (IBM Corp., Armonk, NY, USA). Frequencies and percentages for categorical data were conducted. Moreover, sensitivity and specificity for *CT* and *US* were also approached to summarize the effectiveness of the two testing options in diagnosing acute appendicitis.

### **Ethical Considerations**

The current study was primarily proposed to the Dallah Hospital ethical committee before the data collection process, study was approved to be conducted.

### **Results**

During the current study duration, 720 out of 5,100 patients were differentially diagnosed with appendicitis in the *ER* department. All patients were requested to do radiological workup as well as laboratory investigations for diagnosis confirmation.

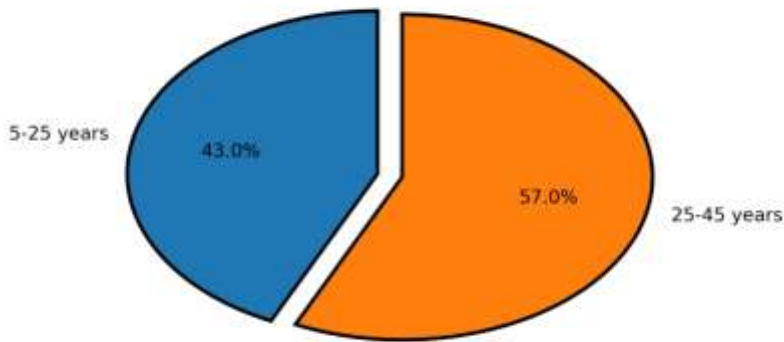
### **Radiological findings**

Out of these patients, 618 patients conducted *US* abdomen/pelvis, and only 15 (2.4%) showed positive appendicitis findings, while 603 (97.6%) indicated negative findings.

*CT* was requested for the negative *US* when clinical manifestations were still suggestive, further confirmation of *US* findings or detection of other related abdominal findings, *CT* abdomen were found reported among 203 patients, among which 8 (4.0%) were found positive for appendicitis while 1 (96%) were negative.

### **Specificity and Sensitivity of Ultrasound and Computed Tomography modalities**

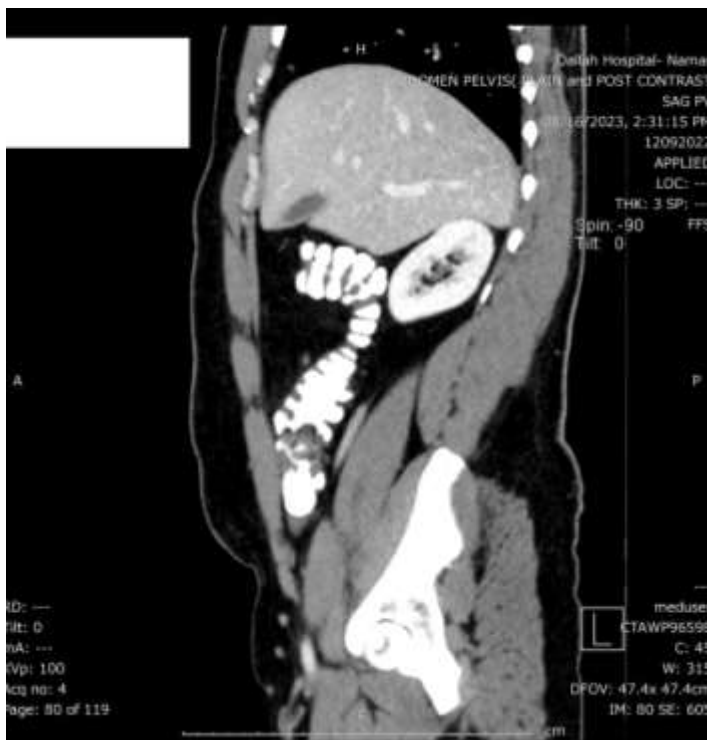After the operation room registry and histopathological laboratory checks; 21 appendectomy were found to be approached. Among these 12 (57%) were females while 9 (43%) were males. Appendicitis patient's ages ranged from 25 to 45 years old among 12 participants (57%), while 9 participants (43%) were between 5 and 25 years old (Figure 1).



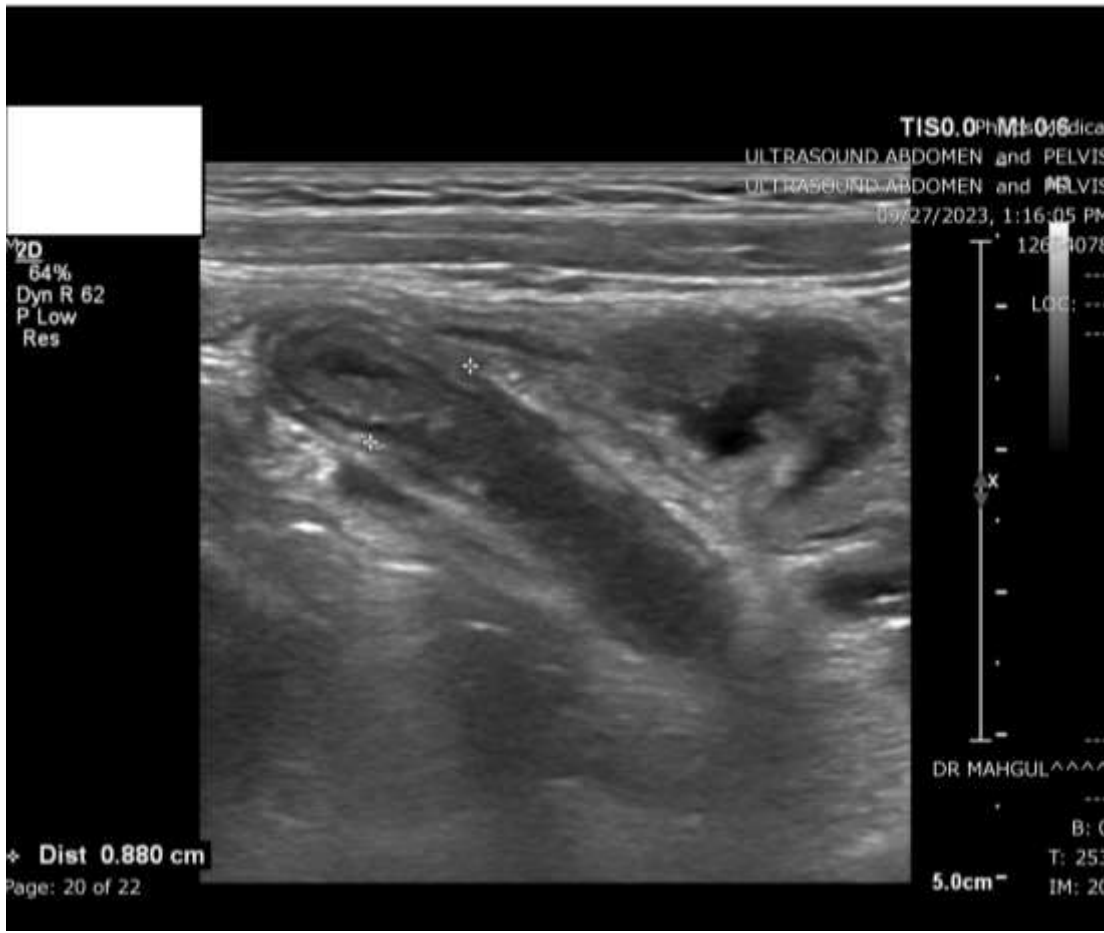
**Figure(1):**Prevalence of appendicitis patients in the current study according to Age

Based on the performance of the two tests, *CT* and *US*, their sensitivity and specificity were calculated; *CT* imaging had a sensitivity of 90.0% (CI: 55.50% to 99.75%) and a specificity of 100.0% (CI: 99.38% to 100.00%) in diagnosing acute appendicitis. *US* imaging on the other hand, had a sensitivity of 71.43% (CI: 47.82% to 88.72%) and a specificity of 100% (CI: 99.38% to 100.00%) regarding acute appendicitis diagnosis (Figure 2 & Figure 3).

All these 21 patients had *US* abdomen/pelvis, among which appendicitis findings were positive in 15 patients (71.4%). Moreover, only 9 out of 21 patients were found to undergo an abdominal *CT* investigation, and the findings of appendicitis were positive in 8 participants (88.9%).



**Figure (2):** Enhanced CT abdomen & pelvis, sagittal view showing inflamed retro-cecal Appendix.



**Figure (3):** right iliac fossa superficial scanning showing tubular blind-ended structure of 0.880 cm.

**Laboratory findings**

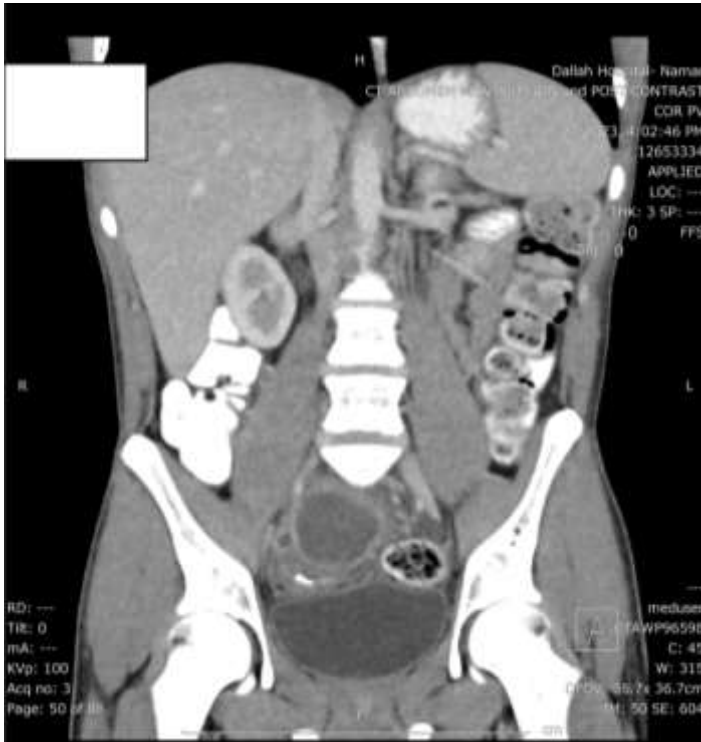
All appendicitis patients had *TWBCs* level determination; only 9 participants (42.8%) were found to have a high *TWBCs* count. Moreover, only 9 appendicitis patients conducted *CRP* level; out of which 6 participants (66.7%) were reactive. Furthermore, serum creatinine level was found to be investigated among 10 appendicitis patients; all of them (100%) had high serum creatinine levels. Regarding pathological findings, all 21 patients (100%) had features of suggestive acute appendicitis, as depicted in (Table 1).

Table (1): Laboratory findings of appendicitis patients included in the current study

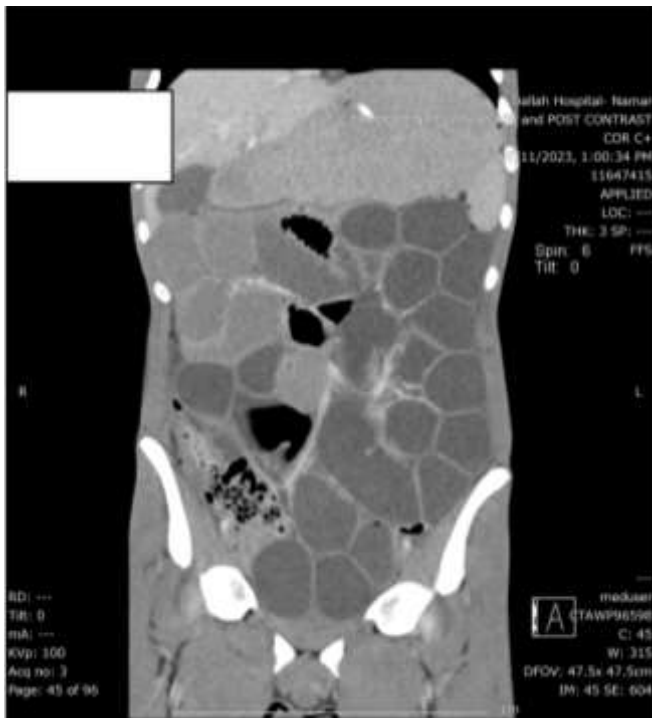Investigation	Conducted among (No. participants)	Reactive or high among (No. participants)
<b>TWBCs</b>	21	9 (42.8%)
<b>CRP</b>	9	6 (66.7%)
<b>Creatinine</b>	10	10 (100%)

**Appendicitis Incidence and complications**

Appendicitis incidence per three months was  $21/5,100 = 0.00411$  (4.11 per 1,000 population). Two patients out of 21 (9.5%) suffered consequences of appendicitis among the study population. One participant (4.7%) developed an appendicular abscess while one participant (4.7%) experienced postoperative complications (Figures 4 & Figure 5).



**Figure (4):** Enhanced CT abdomen & pelvis, coronal view showing right pelvic thick peripherally enhancing walled cystic lesion (Appendicular abscess).



**Figure (5):** Enhanced CT abdomen & pelvis, coronal view showing small bowel obstruction complicating appendectomy.

## Discussion

This study aimed to determine the specificity and sensitivity of *US* and *CT* radiological findings of appendicitis as well as to investigate the prevalence of various appendicitis laboratory findings and its clinical complications among populations in Riyadh City, Saudi Arabia.

In the current study, we found that the sensitivity of *CT* in detecting acute appendicitis findings is almost 90% while its specificity was 100%. This finding antagonizes the results concluded by a study done at King Fahad Hospital in 2019, as the *CT* acute appendicitis diagnosis sensitivity of 86% and specificity of only 16.7% estimates were reported.<sup>[2]</sup> Moreover, a more recent study (2022) indicated that *CT* imaging had a sensitivity of almost 98% and a specificity of 16.7% in detecting acute appendicitis. Nevertheless, aligning with the current findings, a prospective study titled: “Suspected acute appendicitis: is ultrasonography or computed tomography the preferred imaging technique?” conducted by Pickuth and colleagues indicated that *CT* was found to be more sensitive (95%) than *US* (87%) in patients suspected of acute appendicitis.<sup>[11, 12]</sup>

Regarding the *US*, the sensitivity of detecting acute appendicitis was determined in the current study as 71.43% (CI: 47.82% to 88.72%) and a specificity of 100% in detecting acute appendicitis. However, a sensitivity of *US* as low as 37% and a very similar specificity (100%) have both been reported among populations of Unaizah, Qassim, Saudi Arabia. These differences in findings may be attributed to different radiological protocols, and machine models as well as difficulties associated with patients’ preparations regarding *US* abdomen/pelvis investigation.<sup>[11, 12]</sup>

*TWBCs* and precisely neutrophils play a significant role in the diagnosis of acute appendicitis. Ishizuka and colleagues showed that neutrophil count is an indication of the type of appendicitis and helps to give the definitive diagnosis. The current study found that only almost (43%) of appendicitis patients have a high *TWBCs* count, this finding aligns with another study conducted among appendicitis patients in Khamis Mushayt City, Saudi Arabia.<sup>[13, 14]</sup>

Regarding creatinine serum level, it was found to be high among all tested participants in the current study. This finding is the first of its kind among the Saudi population - to our knowledge. Association of right hydronephrosis with complicated appendicitis has been previously documented, it has been suggested that the spread of peri-appendiceal inflammation may be the clinical mechanism of action. Taking this into account, it is assumed that serum creatinine levels are to be increased during acute appendicitis as it may alter kidney function. To support this finding; a recently published study (2022) titled “Acute Kidney Injury in Children with Acute Appendicitis” concluded the same finding among pediatric appendicitis patients.<sup>[15, 16]</sup>

Several limitations of the current study need to be addressed when considering study findings; the sample size of participants included is considered low. Moreover, as the nature of the study is retrospective, several data might have been missed as many participants departed the hospital before conducting the required investigations. Furthermore, positive *US* findings may lead to *CT* abolition to avoid unnecessary radiation exposure, especially among females, or to reduce cost. Lastly, the Alvarado score could not be applied as several related data were not found to be available among most participants in the patient’s registry system.

## Conclusions

*US* modality imaging sensitivity was determined to be relatively low; even lower estimates have been reported in the literature. Moreover, serum creatinine was found to be elevated among all checked appendicitis patients. Further research with a larger sample size is needed to be conducted to further support the current findings.

## References

- [1] Mishra RK, Hanna GB, Cuschieri A: Laparoscopic versus Open Appendectomy for the Treatment of Acute Appendicitis. *World J of Lapar Surg with DVD*. 2008; 1:19-28. 10.5005/jp-journals-10007-1043
- [2] Alshebromi MH, Alsaigh SH, Aldhubayb MA: Sensitivity and specificity of computed tomography and ultrasound for the prediction of acute appendicitis at King Fahad Specialist Hospital in Buraidah, Saudi Arabia. *Saudi Med J*. 2019; 40:458-462. 10.15537/smj.2019.5.23777
- [3] Bhangu A, Søreide K, Di Saverio S: Acute appendicitis: Modern Understanding of Pathogenesis, Diagnosis, and Management. *The Lancet*. 2015; 386:1278-1287. 10.1016/s0140-6736(15)00275-5
- [4] Nwashilli N, Agogbua C: Acute Appendicitis at University of Benin Teaching Hospital, Benin City. *Nigerian J Surg Sci*. 2018; 28:34.
- [5] Schwerek WB, Wichtrup B, Maroske D: Ultrasonics in Acute Appendicitis. a Prospective Study. *Dtsch Med Wochenschr*. 1988; 113:493-499. 10.1055/s-2008-1067670
- [6] D'Souza N, Nugent K. Appendicitis. *BMJ Clin Evid*. 2014 Dec 8; 2014:0408
- [7] Jamal W: Prevalence, Diagnostic Workup and Management of Appendicitis at Single Academic Institution, Jeddah, Saudi Arabia. *Int J Surg Med*. 2020; 7:1-10.
- [8] Fujita T: Appendectomy: Negative Appendectomy No Longer Ignored. *Arch Surg*. 2007; 1032:10.1001/archsurg.142.11.1023
- [9] Shogilev D, Duus N, Odom S: Diagnosing Appendicitis: Evidence-Based Review of the Diagnostic Approach in 2014. *West J Emerg Med*. 2014; 15:859-871. 10.5811%2Fwestjem.2014.9.21568
- [10] Yu D, Gu C, Zhang S: Ultrasound Features and The Diagnostic Strategy of Subhepatic Appendicitis. *Ann Transl Med*. 2020; 8:1083. 10.21037%2Fatm-20-5265
- [11] Pickuth D, Heywang-Köbrunner SH, Spielmann RP: Suspected Acute Appendicitis: Is Ultrasonography or Computed Tomography the Preferred Imaging Technique? *Eur J Surg*. 2000; 166:315-319. 10.1080/110241500750009177
- [12] AlJohani M, AlSulaim L, AlHarbi A: Accuracy of Diagnostic Modalities in Suspected Appendicitis in King Saud Hospital, Unaizah, Qassim, Saudi Arabia-Retrospective Cohort Study. *Int J of Surg Open*. 2022; 47:100553. 10.1016/j.ijso.2022.100553
- [13] Ishizuka M, Shimizu T, Kubota K: Neutrophil-to-Lymphocyte Ratio Has a Close Association with Gangrenous Appendicitis in Patients Undergoing Appendectomy. *Int Surg*. 2012; 97:299-304. 10.9738/CC161.1.
- [14] Alshahrani SA, Alqahtani MS, Asiri M A: Acute Appendicitis among Saudi and non-Saudi Patients: A Cross-Sectional Based Study. *J Health Med Nurs*. 2017; 42:
- [15] Marzuillo P, Iafusco D, Zanfardino A, Guarino S, Piscopo A, Casaburo F et al. Acute Kidney Injury and Renal Tubular Damage in Children with Type 1 Diabetes Mellitus Onset. *J Clin Endocrinol Metab*. 2021 Jun 16;106(7): e2720-e2737.
- [16] Marzuillo P, Coppola C, Caiazzo R, et al.: Acute Kidney Injury in Children with Acute Appendicitis. *Children (Basel)*. 2022; 27:620. 10.3390/children9050620